

ORIGINAL ARTICLE

Split-face study of melasma patients treated with non-ablative fractionated photothermolysis (1540 nm)

MJ Barysch,^{†,‡} B Rümmelein,^{†,§} I Kolm,[†] MB Karpova,[†] N Schönewolf,[†] I Bogdan Allemann,[†] R Dummer^{†,*}

[†]Department of Dermatology, University Hospital Zurich, Zurich

[‡]Department of Plastic and Reconstructive Surgery, Children's Hospital, Zurich

[§]Dermatological Practice, Medical Centre Sanitas, Kilchberg/Zurich, Switzerland

*Correspondence: R Dummer. E-mail: Reinhard.dummer@usz.ch

Abstract

Background Melasma treatment remains challenging despite various laser systems available, because of potential side-effects and high recurrence rates.

Objective Non-ablative fractionated photothermolysis (FP) is a promising therapeutic method, long-time results comparing treated vs. non-treated site are lacking.

Methods A total of 14 patients were treated with FP in a split-face mode with standardized adjustments in three sessions (weeks 0, 3–4, 6–8, follow-up: 26–28). At each consultation, improvement was evaluated by patients and physicians. Objective assessment was performed using digital photographs and the pigment imaging tool SIAscope[®].

Results Melasma improvement was registered in 83% and 75% of the cases 26–28 weeks after the first treatment based on two evaluations: by patient and by physician, respectively. Digital photography and SIAscope[®] revealed improvement in 54% and 85% after the first, 61% and 85% after the second, 41% and 58% after the third treatment, accordingly, mostly due to reduction of the outline sharpness. Patients with lighter skin complexions revealed significant improvement ranged from slight to moderate ($P = 0.03$). Postinflammatory hyperpigmentation occurred in two cases with skin types III and IV.

Conclusion Non-ablative FP can be considered as a valuable treatment option with short-term improvement in terms of mild reduction and softening the edges of melasma in patients with skin types I/II, if prior topical therapies failed. Treatment of patients with skin types III+ should be critically questioned.

Received: 29 August 2010; Accepted: 1 April 2011

Conflicts of interest

None declared.

Funding sources

The sun screen containing the green tea extract OM24[®] was supplied by Merz Pharma (Switzerland) AG. Marjam Jeanette Barysch and Reinhard Dummer were supported by the Society for Skin Cancer Research (Verein für Hautkrebsforschung, VHKF) and the Gottfried and Julia Bangerter-Rhyner Foundation.

Background

Melasma is a common and nuisance pigment disorder of the skin, mostly affecting women with darker complexions. Besides genetic predisposition and hormonal influences, UV irradiation is a major trigger factor for the development of melasma. Commonly available topical and physical treatments such as hydroquinone, retinoids, azelaic or kojic acids, chemical and mechanical peelings often lack success because of resistance to the agent and fast recurrences of the melasma.^{1–8}

Laser systems are gaining popularity and treatments with several laser systems, e.g. the carbon dioxide or Q-switched alexandrite (755 nm), reduced hyperpigmentation in a number of cases. Nevertheless, high rates of postinflammatory hyperpigmentation and/or long downtime rates are commonly observed as well as melasma recurrence.^{6,9–11} Q-switched frequency doubled neodymium:yttrium-aluminium-garnet (Nd:YAG, 1064/532 nm) and the Q-switched ruby (694 nm) lasers failed in the treatment of melasma using the high fluence modus.^{12–14} Recently, low-fluence Q-switched Nd:YAG lasers proved to be reliable in the treatment

of melasma of skin types III and IV,^{15,16} but retain the risk for depigmentation.¹⁷

Lately, non-ablative fractionated photothermolysis (FP) systems have been suggested for the melasma treatment with an acceptable side-effect profile.

Fractionated photothermolysis induces selective thermal damage in form of micro-beams with a diameter of less than 400 μm . This leads to the formation of microscopic thermal zones (MTZ) affecting collagen fibres and keratinocytes. Column-like necroses of keratinocytes (microscopic epidermal necrotic debris, MEND) develop within the epidermis and enable keratinocytes and dermal components to migrate towards the stratum corneum resulting in the removal of the coagulated substances.^{18,19} Directly after FP application on melasma lesions, melanin can be detected in MENDs within 6 days after the treatment.²⁰ Enlarged melanocytes, commonly observed in melasma lesions, remain reduced in number up to 3 months after a single FP treatment.²¹ These findings suggest that MENDs are acting as 'melanin shuttles', resulting in the elimination of dermal and epidermal melanin.²⁰

In a few clinical studies, an improvement of melasma was yielded after the FP-treatment.^{22,23} Nevertheless, neither long-term effects on Fitzpatrick skin types II–IV nor split-face experiments for the exclusion of interfering co-factors such as decreased exposure to ultraviolet irradiation during the winter months were investigated.

Therefore we opted to evaluate the long-term effects of the FP treatment in melasma patients in a split-face setting using the non-treated half of the face for a direct comparison. Sun screen containing the green tea extract OM24[®] was applied to the whole face.

Materials and methods

The study was performed at the Department of Dermatology, University Hospital Zurich, Switzerland. A total of 14 female patients with symmetric melasma were enrolled upon the receipt of their informed consent. Study protocol followed ethical guidelines of the Declaration of Helsinki (1975) as reflected in the approval by the Zurich cantonal ethics committee (reference number 715).

Inclusion criteria were as follows: symmetric distribution of the melasma, Fitzpatrick skin type II–IV and age above 18 years. Exclusion criteria were as follows: pregnancy or breast feeding, usage of photosensitizing medication, UV exposure 6 weeks prior to the study, usage of pigment reducing topical treatments, herpes labialis or other infectious diseases of the skin within the treated area and immunosuppression. Patients were provided with the sun screen containing the green tea extract OM24[®] (Antidry[®] SUN Crème UVA/UVB SPF 30; Merz Pharma AG, Allschwil, Switzerland) and instructed to apply the cream daily on the whole face and strictly avoid sun exposure during the entire study.

Non-ablative FP (Lux1540 Fractional Laser hand piece; Palomar Medical Technologies, Burlington, VT, USA) was performed with standardized adjustments on one half of the face during three treatment sessions (weeks 0, 3–4, and 6–8) using an energy of 320 MTZ/cm² with a pulse length of 15 ms. Three treatment passes were used with horizontal and vertical overlap of one-third. All patients received the same energy, pulse duration and number of passes regardless of their skin type. The more affected half of the face was chosen for treatment. If both halves of the face were equally affected, the right side of the face was chosen. The last

Table 1 Patient's characteristics with prior treatments and localization of melasma

Age	Skin type	Severity of melasma	Duration of melasma (years)	Prior treatments*	Location
29	2	Strong	2	Azelaic acid	Around the lips, cheeks
43	2	Strong	1.5	Sun screen	Entire face
36	2	Strong	5	Hydroquinone	Cheeks
38	2	Strong	4.5	Hydroquinone	Entire face
42	2	Strong	4	Lactic acid superficial peels	Entire face
49	2	Strong	4	Glycolic acid superficial peel, hydroquinone, fractionated photothermolysis	Entire face
42	3	Strong	22	None	Around the lips
29	3	Strong	3	Hydroquinone	Around the lips, cheeks
29	3	Strong	3	Topical retinoids	Entire face
34	3	Strong	2	Hydroquinone	Entire face
35	3	Strong	5	Lactic acid superficial peels	Around the lips, cheeks
58	4	Strong	4	Hydroquinone	Cheeks
40	4	Strong	5	Azelaic acid, suns screen	Entire face
36	4	Strong	14	Azelaic acid	Entire face

*Applied for at least one season.

follow-up visit was performed 26–28 weeks after the first treatment session.

Standardized digital photographs were taken prior to each treatment session and at the last visit. At each visit, pigmentation grade of the treated side was evaluated separately by the patient and the physician. Pain during the treatment as well as redness and scaling of the skin after the treatment were evaluated by the patient at each visit. Evaluation scores were ranged from 0 to 5: 0 – ‘none’; 1 – ‘very low’; 2 – ‘low’; 3 – ‘moderate’; 4 – ‘high’; and 5 – ‘very high’.

Treatment effectiveness was objectively measured by the pigment distribution using the pigment imaging technology tool SIAscope® (Physiometrics, SIAscope V non contact; Astron Clini-

ca, Cambridgeshire, UK). Improvement scores ranged from 0 to 3: 0 – ‘worsening’; 1 – ‘no improvement’; 2 – ‘moderate improvement’; and 3 – ‘strong improvement’. Improvement was assigned as ‘strong’ if the desirable changes in the appearance of the melasma lesions were striking and as ‘moderate’ if the changes were noticeable but required a closer look.

Statistical analysis

Statistical analysis was performed using GRAPHPAD PRISM software version 5.00 (GraphPad Software, San Diego, CA, USA). *P*-values of less than 0.05 were considered to be statistically significant. For evaluation of the treatment effectiveness, one-sample *t*-test was performed. Two-way ANOVA was used for evaluation of the clinical outcome and erythema index for each skin type. Mean improvement scores (MIS), standard deviation (SD) and confidence intervals (CI) of 95% were computed.

Table 2 Pigment evaluation by patients and physicians

Weeks	Mean pigment (95% CI)	
	Patient	Physician
0	3.9 (3.4–4.4)	3.6 (3.2–3.9)
3–4	2.9 (2.4–3.4)	2.8 (2.3–3.3)
6–8	2.5 (2.1–2.9)	2.5 (2.1–2.9)
26–28	2.0 (1.5–2.5)	2.3 (1.5–3.0)

Scores range from 0 ‘none’ to 5 ‘severe’.

Results

A total of 14 patients with a mean age of 38.5 years (±8.1) were enrolled. All patients were suffering from melasma with a strong intensity for a mean time of 5.6 years (range: 1.5–22, SD: 5.6, CI: 2.4–8.9). Prior treatments were performed for at least one season and stopped at least 6 months prior to the study. According to

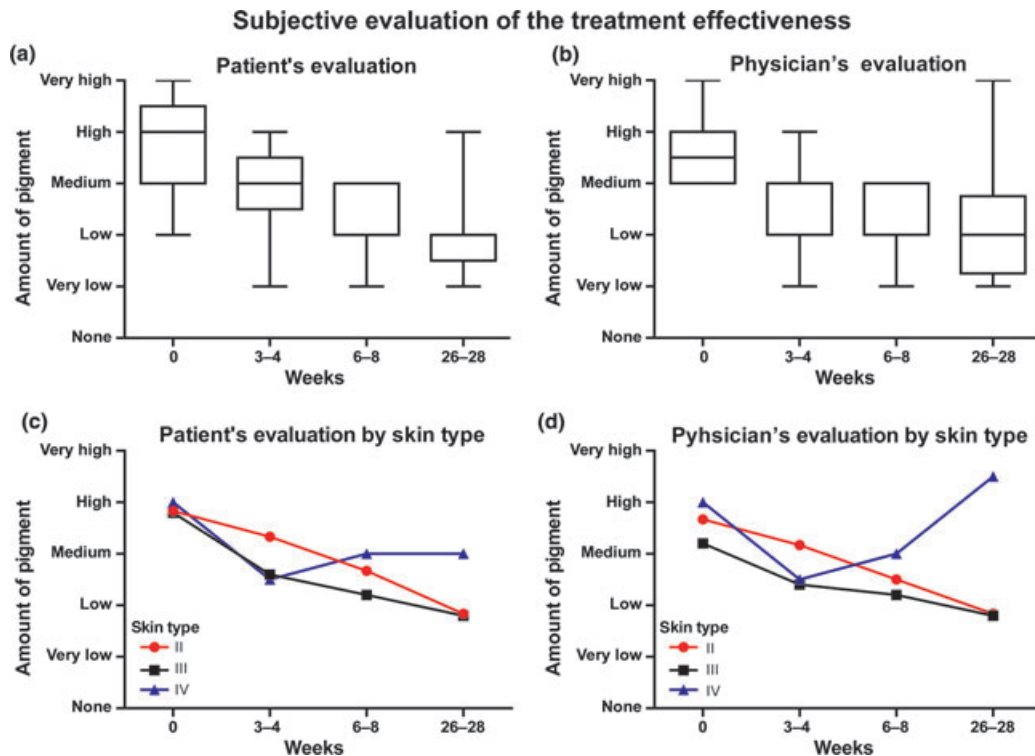


Figure 1 Subjective evaluation of the treatment effectiveness performed by patients and physicians. (a) and (b) show mean evaluation values with their whiskers from minimum to maximum over the treatment time course. (c) and (d) show evaluation curves over the treatment time course divided by skin types.

Objective evaluation of pigment distribution by SIAscope®
Improvement scores: 0 – ‘worsening’, 1 – ‘none’, 2 – ‘slight’, 3 – ‘moderate’.

Evaluation with SIAscope® revealed significant improvement of melasma after each treatment ($P < 0.005$). At weeks 3–4 and 6–8, 85% (11/13) of patients experienced an improvement: 55% (6/13) in terms of pigment reduction and the remaining 45% (5/13) in terms of reduced sharpness of the outlines resulting in less striking appearance of melasma lesions; 23% (2/13) of patients showed worsening of their melasma. At weeks 26–28, only 58% (7/12) of

patients experienced an improvement of which 86% (6/7) were due to a reduction of the lesion’s silhouette. Of all the patients, 25% (3/12) experienced no improvement and 17% (2/12) showed worsening of the lesions because of postinflammatory hyperpigmentation. Overall, clinical outcome was significantly better for patients with skin type II ($P = 0.03$) (Table 3, Figs 2 and 4).

Discussion

Fractionated photothermolysis raised hope to be an effective treatment option for melasma patients as its mode of action suggests

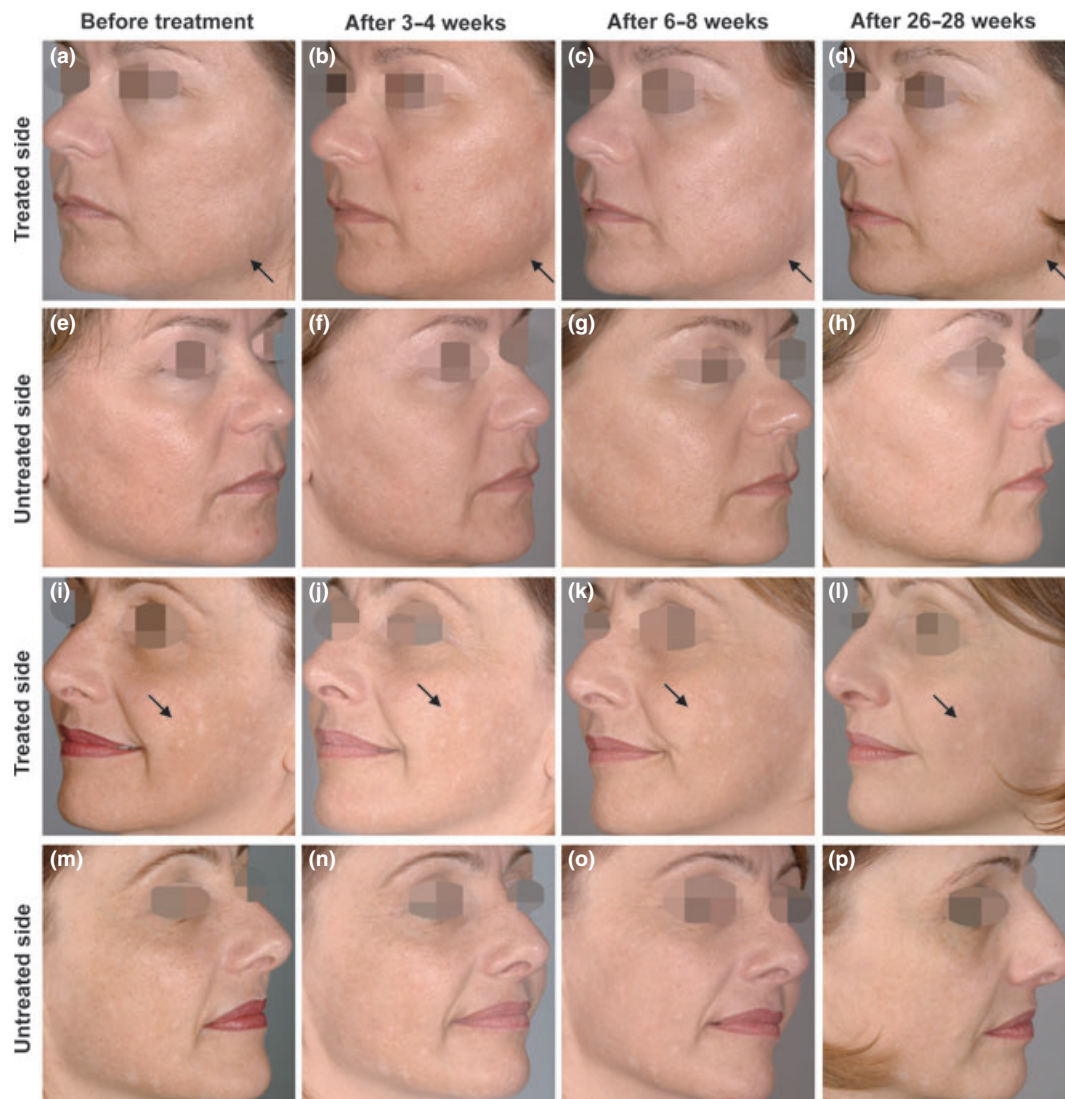


Figure 3 Course of clinical improvement of two melasma patients evaluated by digital photography. Photographs (a), (e), (i) and (m) represent pretreatment condition; (b), (f), (j) and (n) represent the condition after first laser treatment session (weeks 3–4); (c), (g), (k) and (o) represent the condition after 2nd treatment (weeks 6–8); (d), (h), (l) and (p) represent the condition after third treatment (weeks 26–28). First row of each patient shows treated side (a–d and i–l) and lower row of each patient shows untreated side (e–h and m–p). Note the discrete pigment reduction and less visible lesions on treated sides because of de-sharpening of outline (indicated by arrows).

Table 3 Objective effects measured by SIAscope®

Effects	Weeks		
	3–4	6–8	26–28
Moderate improvement	0	0	0
Slight improvement	11*	11*	7†
No improvement	0	0	3
Worsening	2	2	2

Numbers correspond to numbers of patients.

* In five († in six) cases slight improvement in terms of reduced sharpness of outline of the lesions.

melanin elimination with a low rate of side-effects. To the best of our knowledge, only one single case²⁴ and three clinical study reports^{22,23,25} discuss the clinical outcome of melasma treated by FP. In one of these studies, 25 Asian patients were treated with 15 mJ/MTZ in four treatment sessions over 36 weeks.

Improvement was observed in 40 to 60% and postinflammatory hyperpigmentation occurred in 13% of cases.²² Another study enrolled 10 melasma patients with skin types III and IV and performed FP treatment with 6–12 mJ/MTZ during 4–6 sessions 1–2 weeks apart. Pigment reduction of 75–100% based on patients' and physicians' evaluation was reached in 50% and 60% respectively.²³ However, the follow-up period was rather short, with a maximum of 12 weeks.

In this study, a slight but significant pigment reduction was yielded by weeks 26–28 evaluated using digital photography and the pigment analyser SIAscope® in 50% (6/12) and 58% (7/12) respectively. However, it needs to be stated that the majority of improvements were attributed to softening of the outlines, resulting in less prominent appearance of melasma lesions. Of all the patients, 58% (7/12) improved slightly, 8% (1/12) improved moderately and 17% (2/12) had no improvement as evaluated in comparison with the non-treated half of the face; 17% (2/12) of

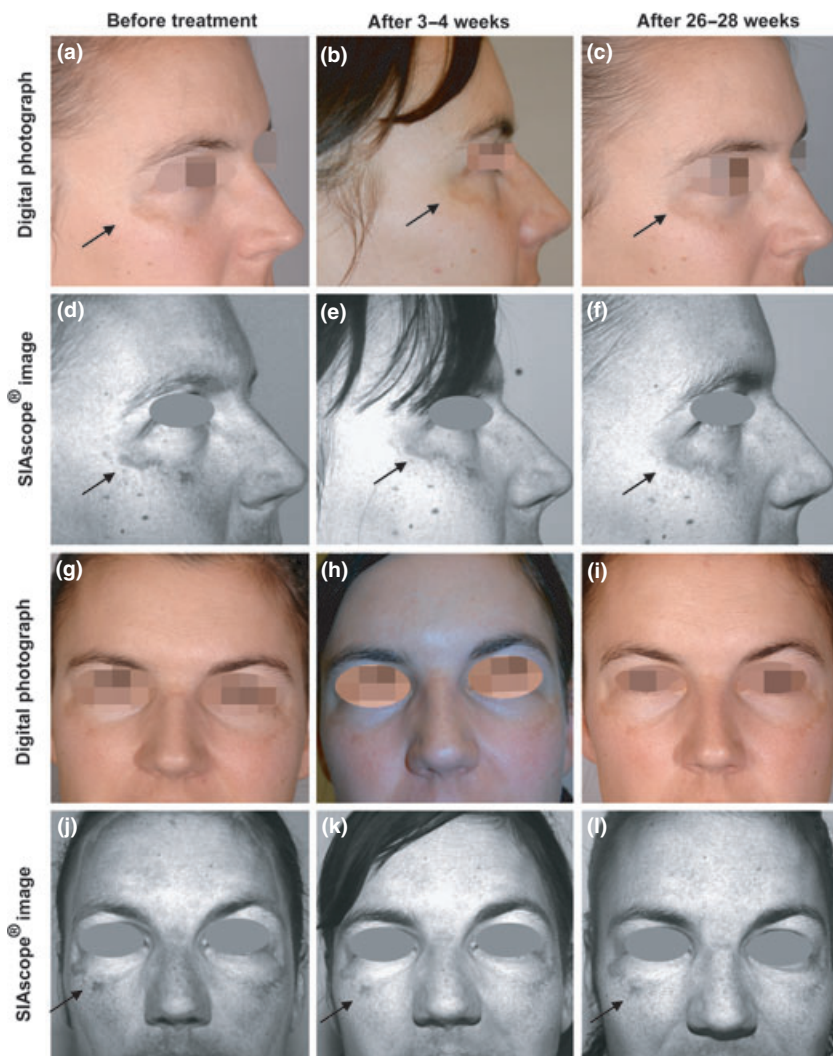


Figure 4 Melanin distribution during the treatment course detected by digital photography and SIAscope®. Images (a), (d), (g) and (j) represent pretreated condition; (b), (e), (h) and (k) represent condition after first laser session (weeks 3–4); (c), (f), (i) and (l) represent the condition after last laser treatment (weeks 26–28). Upper two panels show treated right side of the patient's face and lower two panels show the full face for comparison with the untreated side. Note de-sharpening of the outline but less pigment fading.

patients suffered from worsening of the lesions because of postinflammatory hyperpigmentations (one patient with skin type III and one with skin type IV). Consistent with the current literature,²⁶ there were no downtimes because of the wound healing and no severe side-effects besides the two cases of postinflammatory hyperpigmentation in patients with darker skin complexions.

The presented data are congruent with prior studies, although in this study a higher proportion of patients with lighter skin complexions were included. However, comparable results may partly be explained by the fact that present comparison was made between the treated and non-treated sides of patient's face. As melasma commonly improves during winter, when laser treatments are preferentially performed, the outcome of previous clinical studies may have been influenced by additional co-factors, such as decreased UV-exposure.

Effects of the sun screen containing the green tea extract OM24[®] in our study was unclear. Whole-face application may have diminished the improvement of the treated compared with the non-treated face side as OM24[®] showed photochemo-protective properties *in vivo*,²⁷ and catecholamines-dependant depigmentation *in vitro*.²⁸ Mechanistically, OM24[®] is suggested to have photo- and chemo-protective properties because of the reduction of UVB-mediated epithelial damage.²⁷

The highest pigment reduction was achieved after the first two FP treatments, while after 26–28 weeks from the treatment start melasma partially reoccurred. The lack of long-lasting effects in melanin reduction may be attributed to non-curative melanin elimination via MENDs. Modulation of the Wnt and DKK (Dickkopf) signalling pathways are commonly observed in pigmentation disorders.^{29,30} It may be suggested that melasma treatment without targeted inhibition of the Wnt and DKK pathways within the dermis and epidermis may be ineffective for long-term effects.

The present work is the first study evaluating the FP regimen in a split-face mode for the melasma treatment in patients with skin types II–IV and long follow-up period (more than 6 months). Our results emphasize that indication of FP for the treatment of melasma, particularly in patients with darker skin complexions, needs to be critically evaluated. Before opting for invasive treatment modalities, all conservative treatment options should be explored. However, compared with the other laser treatment modalities, such as Alexandrite laser, FP shows considerably lower side-effects and has the tremendous advantage of almost no downtime requirements because of the wound healing.

To conclude, non-ablative FP can be considered as a valuable tool for a mild reduction of melasma in patients with skin types I and II if topical treatments have failed. Particularly softening of the lesion's edges shall be expected providing a more even skin complexion. FP treatment for patients with darker skin types (III+) requires high caution because of the risk of postinflammatory hyperpigmentation and treatment should be performed, if at all, with decreased densities.

References

- 1 Griffiths CE, Finkel LJ, Ditre CM, Hamilton TA, Ellis CN, Voorhees JJ. Topical tretinoin (retinoic acid) improves melasma. A vehicle-controlled, clinical trial. *Br J Dermatol* 1993; **129**: 415–421.
- 2 Khunger N, Sarkar R, Jain RK. Tretinoin peels versus glycolic acid peels in the treatment of Melasma in dark-skinned patients. *Dermatol Surg* 2004; **30**: 756–760. discussion 760.
- 3 Haddad AL, Matos LF, Brunstein F, Ferreira LM, Silva A, Costa D Jr. A clinical, prospective, randomized, double-blind trial comparing skin whitening complex with hydroquinone vs. placebo in the treatment of melasma. *Int J Dermatol* 2003; **42**: 153–156.
- 4 Sarkar R, Bhalla M, Kanwar AJ. A comparative study of 20% azelaic acid cream monotherapy versus a sequential therapy in the treatment of melasma in dark-skinned patients. *Dermatology* 2002; **205**: 249–254.
- 5 Sarkar R, Kaur C, Bhalla M, Kanwar AJ. The combination of glycolic acid peels with a topical regimen in the treatment of melasma in dark-skinned patients: a comparative study. *Dermatol Surg* 2002; **28**: 828–832. discussion 832.
- 6 Gupta AK, Gover MD, Nouri K, Taylor S. The treatment of melasma: a review of clinical trials. *J Am Acad Dermatol* 2006; **55**: 1048–1065.
- 7 Hurley ME, Guevara IL, Gonzales RM, Pandya AG. Efficacy of glycolic acid peels in the treatment of melasma. *Arch Dermatol* 2002; **138**: 1578–1582.
- 8 Cestari T, Arellano I, Hexsel D, Ortonne JP. Melasma in Latin America: options for therapy and treatment algorithm. *J Eur Acad Dermatol Venereol* 2009; **23**: 760–772.
- 9 Manaloto RM, Alster T. Erbium:YAG laser resurfacing for refractory melasma. *Dermatol Surg* 1999; **25**: 121–123.
- 10 Nouri K, Bowes L, Chartier T, Romagosa R, Spencer J. Combination treatment of melasma with pulsed CO2 laser followed by Q-switched alexandrite laser: a pilot study. *Dermatol Surg* 1999; **25**: 494–497.
- 11 Angsuwarangsee S, Polnikorn N. Combined ultrapulse CO2 laser and Q-switched alexandrite laser compared with Q-switched alexandrite laser alone for refractory melasma: split-face design. *Dermatol Surg* 2003; **29**: 59–64.
- 12 Tse Y, Levine VJ, McClain SA, Ashinoff R. The removal of cutaneous pigmented lesions with the Q-switched ruby laser and the Q-switched neodymium: yttrium-aluminum-garnet laser. A comparative study. *J Dermatol Surg Oncol* 1994; **20**: 795–800.
- 13 Goldberg DJ. Benign pigmented lesions of the skin. Treatment with the Q-switched ruby laser. *J Dermatol Surg Oncol* 1993; **19**: 376–379.
- 14 Taylor CR, Anderson RR. Ineffective treatment of refractory melasma and postinflammatory hyperpigmentation by Q-switched ruby laser. *J Dermatol Surg Oncol* 1994; **20**: 592–597.
- 15 Jeong SY, Shin JB, Yeo UC, Kim WS, Kim IH. Low-fluence Q-switched neodymium-doped yttrium aluminum garnet laser for melasma with pre- or post-treatment triple combination cream. *Dermatol Surg* 2010; **36**: 909–918.
- 16 Choi M, Choi JW, Lee SY *et al.* Low-dose 1064-nm Q-switched Nd:YAG laser for the treatment of melasma. *J Dermatolog Treat* 2010; **21**: 224–228.
- 17 Chan NP, Ho SG, Shek SY, Yeung CK, Chan HH. A case series of facial depigmentation associated with low fluence Q-switched 1,064 nm Nd:YAG laser for skin rejuvenation and melasma. *Lasers Surg Med* 2010; **42**: 712–719.
- 18 Manstein D, Herron GS, Sink RK, Tanner H, Anderson RR. Fractional photothermolysis: a new concept for cutaneous remodeling using microscopic patterns of thermal injury. *Lasers Surg Med* 2004; **34**: 426–438.
- 19 Hantash BM, Bedi VP, Sudireddy V, Struck SK, Herron GS, Chan KF. Laser-induced transepidermal elimination of dermal content by fractional photothermolysis. *J Biomed Opt* 2006; **11**: 041115.
- 20 Laubach HJ, Tannous Z, Anderson RR, Manstein D. Skin responses to fractional photothermolysis. *Lasers Surg Med* 2006; **38**: 142–149.

- 21 Goldberg DJ, Berlin AL, Phelps R. Histologic and ultrastructural analysis of melasma after fractional resurfacing. *Lasers Surg Med* 2008; **40**: 134–138.
- 22 Lee HS, Won CH, Lee DH *et al.* Treatment of melasma in Asian skin using a fractional 1,550-nm laser: an open clinical study. *Dermatol Surg* 2009; **35**: 1499–1504.
- 23 Rokhsar CK, Fitzpatrick RE. The treatment of melasma with fractional photothermolysis: a pilot study. *Dermatol Surg* 2005; **31**: 1645–1650.
- 24 Tannous ZS, Astner S. Utilizing fractional resurfacing in the treatment of therapy-resistant melasma. *J Cosmet Laser Ther* 2005; **7**: 39–43.
- 25 Naito SK. Fractional photothermolysis treatment for resistant melasma in Chinese females. *J Cosmet Laser Ther* 2007; **9**: 161–163.
- 26 Chan HH, Manstein D, Yu CS, Shek S, Kono T, Wei WI. The prevalence and risk factors of post-inflammatory hyperpigmentation after fractional resurfacing in Asians. *Lasers Surg Med* 2007; **39**: 381–385.
- 27 Mnich CD *et al.* Green tea extract reduces induction of p53 and apoptosis in UVB-irradiated human skin independent of transcriptional controls. *Exp Dermatol* 2009; **18**: 69–77.
- 28 Sato K, Toriyama M. Depigmenting effect of catechins. *Molecules* 2009; **14**: 4425–4432.
- 29 Chien AJ, Conrad WH, Moon RT. A Wnt survival guide: from flies to human disease. *J Invest Dermatol* 2009; **129**: 1614–1627.
- 30 Goyarts E, Muizzuddin N, Maes D, Giacomoni PU. Morphological changes associated with aging: age spots and the microinflammatory model of skin aging. *Ann N Y Acad Sci* 2007; **1119**: 32–39.

Supporting Information

Additional Supporting Information may be found in the online version of this article:

Figure S1 Intensity of erythema after three FP treatment sessions. The boxplots illustrate each skin type group II, III and IV. Note the significantly higher erythema scores in patients with skin type II compared with patients with skin type III. Patients with skin type IV presented insufficient data for complete statistical evaluation.

Please note: Wiley-Blackwell are not responsible for the content or functionality of any supporting materials supplied by the authors. Any queries (other than missing material) should be directed to the corresponding author for the article.